

Lyell Syndrome in the Pediatric Emergency Room of the University Hospital Center (UHC) Gabriel Toure

Dembele Adama^{1,*}, Maiga Belco¹, Cisse Mohamed Elmouloud¹, Doumbia Abdoul Karim¹, Cissoko Nia¹, Coulibaly Oumar¹, Sacko Karamoko¹, Issa Amadou², Dembele Guediouma¹, Karabinta Yamoussa³, Coulibaly Yacaria², Togo Pierre¹, Sidibe Lala Ndrainy¹, Konate Djeneba¹, Diall Hawa Gouro¹, Traore Kalirou¹, Kone Oumou¹, Ahamadou Ibrahim¹, Diakite Abdoul Aziz¹, Konare Awa¹, Sylla Fatou⁴, Togo Boubacar¹

¹Department of Paediatrics, Gabriel Toure University Hospital, Bamako, Mali

²Department of Paediatric Surgery, Gabriel Toure University Hospital, Bamako, Mali

³Paediatrics Unit, Hospital of Dermatology, Bamako, Mali

⁴Department of Paediatrics, University Hospital Institute of Tropical Ophthalmology of Africa (ITOA), Bamako, Mali

Email address:

admadembele2206docht@yahoo.fr (D. Adama)

*Corresponding author

To cite this article:

Dembele Adama, Maiga Belco, Cisse Mohamed Elmouloud, Doumbia Abdoul Karim, Cissoko Nia, Coulibaly Oumar, Sacko Karamoko, Issa Amadou, Dembele Guediouma, Karabinta Yamoussa, Coulibaly Yacaria, Togo Pierre, Sidibe Lala Ndrainy, Konate Djeneba, Diall Hawa Gouro, Traore Kalirou, Kone Oumou, Ahamadou Ibrahim, Diakite Abdoul Aziz, Konare Awa, Sylla Fatou, Togo Boubacar. Lyell Syndrome in the Pediatric Emergency Room of the University Hospital Center (UHC) Gabriel Toure. *Science Journal of Public Health*. Vol. 10, No. 3, 2022, pp. 106-109. doi: 10.11648/j.sjph.20221003.11

Received: April 14, 2022; Accepted: May 3, 2022; Published: May 12, 2022

Abstract: *Introduction:* Toxic epidermal necrolysis (TEN) or Lyell syndrome is the most severe form of toxidermia. It is clinically characterised by a generalised exanthema with a skin detachment of more than 30% of the body surface area, which differentiates it from Stevens-Johnson syndrome (SJS), which affects less than 10% of the body surface area. Its management is essentially symptomatic. The aim of our study is to investigate the clinical, therapeutic and evolutionary aspects of Lyell syndrome. *Materials and Method:* We conducted a retrospective prospective cross-sectional and descriptive study over a period of 5 years (from 1 January 2014 to 31 December 2018). It concerned children from 1 month to 15 years old. Data were collected using a pre-established survey form and inpatient records. After informed consent from parents and the Head of Department, all information was collected in strict confidentiality. *Results:* During the study period, we were able to collect 10 patients meeting our inclusion criteria out of 9050 hospitalizations, or a frequency of 0.11%. The sex ratio was 4. The age group (6 months to 5 years) was the most affected with 60% of cases. Almost all patients (90%) consulted for skin lesions. The drugs frequently incriminated were non-steroidal anti-inflammatory drugs and anti-epileptics in equal proportions (20%). In 4 patients (40%), no drug could be clearly incriminated. On physical examination, NIKOLSKI's sign was found in 90% of patients. Management was essentially based on rehydration, antibiotic therapy, analgesics and local care. However, mortality remains very high (7 out of 10 patients). *Conclusion:* A rare but very serious pathology, Lyell syndrome has a poor prognosis in our context.

Keywords: Lyell's Syndrome, Paediatrics Emergencies, UHC Gabriel Toure, Mali

1. Introduction

Toxic epidermal necrolysis (TEN) or Lyell's syndrome is the most serious form of toxidermia, induced in 70% of cases by a drug [1, 2]. It is therefore an exceptional disease, with

approximately 120 cases per year in France [3]. In Côte d'Ivoire, it accounts for 27% of toxic epidermal necrolysis [4]. Clinically, it is characterised by a generalised exanthema with a skin detachment of more than 30% of the body surface area, which differentiates it from Stevens-Johnson syndrome (SJS), which affects less than 10% of the body surface area [1]. It is

accompanied by a high mortality rate of 25-50% [5, 6]. Sulphonamides, non-steroidal anti-inflammatory drugs (NSAIDs) and anticonvulsants are the drugs most frequently implicated [1]. The pathophysiology remains poorly understood, but appears to be related to a probably cytotoxic cell-mediated immunological process [7]. Treatment is essentially symptomatic and is best carried out in intensive care units [2, 8]. In the department of paediatrics at the CHU-GT, we are increasingly confronted with the management of this pathology. However, to our knowledge, no study has been carried out on this subject; this is why we initiated this work to update practitioners' knowledge of this pathology.

2. Methodology

2.1. Study Setting and Location

Our study took place in the paediatric emergency department of the Gabriel Touré University Hospital in Bamako. Located in the center of the city, this hospital receives patients from all the communes of Bamako and those referred by other localities in Mali. Despite the existence of community health centers and referral health centers, the number of patients is still very high. It is composed of a neonatology service to which the URENI (Intensive Nutritional Recovery and Education Unit) is attached, a general paediatrics service and a paediatric emergency service.

2.2. Type of Study and Inclusion Criteria

This is a retro-prospective, cross-sectional, descriptive study that took place from 01 January 2014 to 31 December 2018, 5 years. We included all children aged from 1 month to 15 years, admitted to the department of paediatrics for Lyell syndrome. The data were collected using a pre-established survey form and the inpatient records. Variables studied included: patient identification, incriminating drugs, clinical examination, management and outcome. Data were entered and analysed using IBM SPSS statistical software version 21 and Word. For all prospective inclusions, verbal informed consent was obtained from parents or carers and confidentiality of patient information was respected. For retrospective inclusions, we obtained consent from the head of the department. We encountered certain difficulties, among others: the size of the sample (10 patients) does not allow us to study all the evolutionary aspects of this disease; the insufficiency of the adequate technical platform and especially the unfavourable socio-economic situation of the parents limiting the etiological and clinical investigations.

3. Results

During our study period, 10 cases of Lyell syndrome were recorded in the paediatric department out of 9050 hospitalizations, or a frequency of 0.11%. Children aged 6 months to 5 years were most affected (6 out of 10 patients) and the sex ratio was 4 (8 boys, 2 girls). Rash was the main reason for consultation (9/10 patients). The majority of patients (8/10)

had no known history of epilepsy. However, 2 patients were epileptic and under treatment. Carbamazepine in 2 patients, Ibuprofen in 2 patients, Cotrimoxazole in 1 patient and Diclofenac in 1 patient were the drugs implicated in the occurrence of Lyell. The mean time from drug intake to onset of symptoms was 10.3 days. The physical examination was dominated by erythema and oral involvement in all patients. NIKOLSKY sign, nasal erosion and ocular involvement were found in 9 patients. In 7 patients, the affected area was assessed to be between 30-60% and 60-80% in 3 patients. Management was mainly based on rehydration, local care and broad spectrum antibiotics. The average length of hospital stay was 7.1 days. All patients presented with sepsis, 7 of whom died.

4. Discussion

Over a period of 5 years, we recorded 10 cases of Lyell syndrome out of 9050 hospitalizations, or a frequency of 0.11%. Our result is identical to that reported by S Siah and coll [2], according to whom the incidence of Lyell syndrome is 0.1% of the general population. Patients aged 6 months to 5 years with an average age of 5.5 years were the most affected. At this age, children are much more susceptible to infections and in our context, are subjected to different treatments, most cases without medical prescription. In Togo from 2000 to 2015, in a study of 14 cases of Lyell and Stevens-Johnson syndromes, the mean age of patients was 10.9 ± 3.9 years [9]. The majority of patients in our study were male, with a sex ratio of 4. This result differs from that reported by Béchir I [1], in whom the majority of patients were female. However, we did not find a link between gender and Lyell syndrome in the literature. The socio-economic conditions of the parents were judged to be poor in seven out of ten patients, which is a general reflection of the Malian population (67% of the Malian population live below the poverty line according to Mali Demographic and Social Survey (5th edition) MDSS-V [10]).

Table 1. Distribution of patients according to socio-economic data.

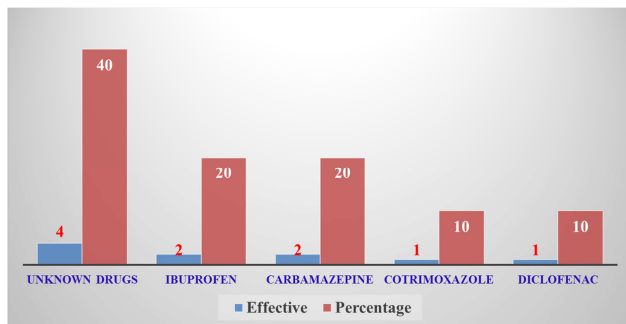
Socio-economic data	Effective	Percentage
Age		
6 months - 5 years	6	60
6 - 10 years old	3	30
11 - 15 years old	1	10
Gender		
Male	8	80
Female	2	20
Economic conditions		
Favourable	3	30
Unfavourable	7	70

This finding is not without consequence, as the majority of our patients were unable to undergo further examinations. The skin lesion was the main reason for consultation (9 out of 10 patients), as in many other authors [1, 3, 4, 6]. Only two out of ten patients had a pathological history of epilepsy. The average time to onset of signs (that is to say the time between the first day of treatment with the incriminating product and the first day of appearance of the skin lesions) was 10.3 days, with extremes of 7 days and 21 days.

Table 2. Distribution of patients according to clinical data.

Clinical data	Effective	Percentage
Reasons for consultation		
Skin rash	9	90
AEG + respiratory distress	1	10
Medical history		
No history	8	80
Epilepsy	2	20
Time to onset of symptoms		
7 - 14 days	7	70
15 - 21 days	3	30

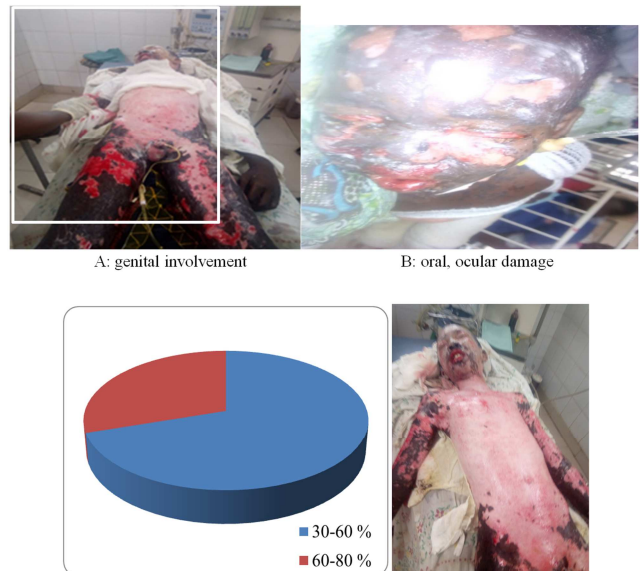
This result is confirmed by previous studies that reported a mean duration of 10 days with an extreme of 30 days [1, 3, 11]. Of the many factors predisposing to the occurrence of the Lyell syndrome, only epilepsy was found in two patients who used a combination of valproic acid plus Carbamazepine in their management. This result confirms the one brought by Béchir I [1] in your study on Management of Lyell's syndrome in intensive care at the University of FES in Morocco in 2013. The incriminated drugs were non-steroidal anti-inflammatory drugs (Diclofenac 10%, Ibuprofen 20%), anti-epileptics (Carbamazepine 20%), antibiotics (Cotrimoxazole 20%). However, in 4 patients (40%), the drugs involved could not be identified.

**Figure 1.** Distribution of patients according to the drugs involved.**Table 3.** Distribution of patients according to clinical examination at entry.

Clinical examination	Effective	Percentage
Erythema	10	100
Nikolsky's sign	9	90
Ocular involvement	9	90
Polypnea	8	80
Hyperthermia	8	80
Tachycardia	6	60
Types of lesions		
Bullae	9	90
Maculo-papule	1	10
Extension of lesions		
Oral involvement	10	100
Erosions of the nose	9	90
Ocular involvement	9	90
Genital lesions	7	70

In China [12], a study on the epidemiology of Lyella syndrome established the role of carbamazepine, allopurinol and penicillins in the occurrence of Lyell syndrome with 17.5%, 9.6% and 7.2% respectively. In addition, traditional Chinese medicine was incriminated in 5.4% of cases. The majority of

patients had a high fever on entry, ranging from 38.5° to 41.1°. This seems to be a general trend as Béchir I also found high fever in his study [1]. All patients had skin lesions on entry with a body surface area of 30-70% affected in 9 out of 10 patients. Our result is identical to that of Béchir [1]. NIKOLSKI's sign (skin detachment following finger pressure leaving the skin bare) was present in 9 patients (90%). Mucosal involvement (nasal, oral and genital) was present in 9 patients. These results are comparable to those reported by Béchir [1].

**Figure 2.** Distribution of patients according to affected area.

Only three of our patients were able to perform certain complementary tests (CBC, CRP, urea, creatinemia, ASAT/ALAT, blood glucose, HIV serology). Anemia and elevated CRP were the abnormalities found in these patients. Our results are different from those of Béchir [1] who found other abnormalities such as hyperglycaemia and positive HIV serology in addition to anaemia. Management was carried out in the paediatric emergency department. The fluids used were colloids and saline. All patients were rehydrated with Ringer's lactate, saline and 5% glucose. The same therapeutic attitude has been observed in many other authors [1, 3, 5, 13]. Antibiotic therapy was performed in all patients, the most commonly used molecules were amoxicillin, Amoxicillin-clavulanic acid and Ceftriaxone). Paracetamol was used as an analgesic/antipyretic in all our patients. According to some authors, in addition to paracetamol, morphine was also used as an analgesic because of the association of other pathologies (cancer). Local care was performed in all our patients: cutaneous (dressing with antiseptics, emollients and local antibiotics); ocular (Vitabact eye drops, tear gel, Tobramycin eye drops, Cebemixin eye drops, atropine eye drops, Vit B12 eye drops); nasal (local antiseptic); buccal (Sodium bicarbonate 14% in combination with xylocaine and fluconazole). Even if the molecules used are not the same, several authors including Béchir [1] also performed the same management in their patients. Two patients were intubated and put on oxygen. Although delicate, oral feeding was possible in 8 patients and two patients received parenteral

nutrition. Despite our working conditions, Lyell syndrome is managed in an intensive care unit with supportive treatment.

Table 4. Distribution of patients according to therapeutic data.

Treatment	Effective	Percentage
Rehydration	10	100
Local care (skin, eye, nose)	10	100
Antibiotics	10	100
Ventilation	2	20
Oxygen therapy	2	20
Possibility of feeding		
Yes	8	80
No	2	20
Length of hospital stay		
< 7 days	4	40
7 - 15 days	4	40
15 - 30 days	2	20

However, due to the lack of technical facilities, our patients only received symptomatic treatment. In Cameroon [14], supportive treatment was the only modality used to achieve complete re-epithelisation of a child with ocular complications of necrotic toxidermia. All our patients developed a clinical picture of sepsis. However, we were unable to confirm this due to lack of blood cultures. We recorded 7 deaths out of 10 patients (70%), a rate largely superior to those of George M and coll [5] and Paquet P and coll [6] who reported 25% and 50% respectively.

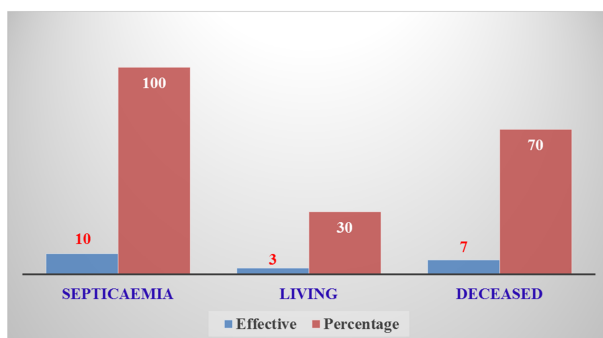


Figure 3. Distribution of patients according to progress.

5. Conclusion

Toxic epidermal necrolysis or LYELL syndrome is a rare but very serious condition. Non-steroidal anti-inflammatory drugs and anti-epileptic drugs are strongly implicated in its occurrence. The poor socio-economic conditions make it difficult to access treatment and the chances of survival of patients who are generally received with very extensive lesions making the prognosis very poor.

References

- [1] Bechir I. Prise en charge du syndrome de Lyell en réanimation. [Thèse de Médecine] Centre Hospitalier Universitaire Hassan II-FES 2013; N°087/13. [Management of Lyell's syndrome in intensive care. [Thesis of Medicine] Hassan University Hospital II-FES 2013; N°087/13].
- [2] S. Siah, A. Baite, H. Bakkali, M. Atmani, K. Prise en Charge du Syndrome de Lyell ou Necrolyse Epidermique Toxique. [Management of Lyell's Syndrome or Toxic Epidermal Necrolysis]. Ann Burns Fire Disasters 2009; 22 (3): 142–146.
- [3] Roujeau JC. Syndromes de Lyell et de Stevens-Johnson. [Lyell and Stevens-Johnson syndromes]. Rev Prat 2007; 57: 1165-70.
- [4] Kourouma S, Sangaré A, Kaloga A, Kouassi I. Syndromes de Stevens-Johnson et de Lyell: étude de 185 cas au CHU de Treichville (Abidjan, Côte d'Ivoire). [Stevens-Johnson and Lyell syndromes: a study of 185 cases at Treichville University Hospital (Abidjan, Ivory Coast)]. Médecine et Santé Tropicales 2014; 24: 94-98.
- [5] Mion G, Bordier E, Daban JL. Atteintes viscérales, physiopathologie et traitement du syndrome de Lyell. [Visceral involvement, pathophysiology and treatment of Lyell syndrome]. Ann Fr Anesth Réa 2006; 25 (9): 1011-1018.
- [6] Paquet, E Jacob, P Damas, GE Piérard. Treatment of drug-induced toxic epidermal necrolysis (Lyell's syndrome) with intravenous human immunoglobulins. Burns J Int Soc Burn Inj 2001; 36: 652-5.
- [7] Baroni A, Ruocco E. Lyell's syndrome. Skin Med 2007; 4 (4): 221-225.
- [8] Pham CH, Gillenwater TJ, Nagengast E, Mc Cullough MC. Combination therapy: Etanercept and intravenous immunoglobulin for the acute treatment of Stevens Johnson syndrome/toxic epidermal necrolysis. Burns J Int Soc Burn Inj 2019; 45 (7): 1634-1638.
- [9] Akakpo AB, Saka B, Abilogoun Chokki AE, Teclessou JN. Stevens Johnson and Lyell syndromes in children in a hospital setting in Lomé, Togo, from 2000 to 2015. Med SanteTrop 2018; 28 (2): 332-333.
- [10] Ministère de la Santé: Enquête Démographique et de Santé du Mali (EDSM-V) Mai 2014. [Ministry of Health: Mali Demographic and Health Survey (EDSM-V) May 2014]. Available on: www.santé.gov.ml.
- [11] Nassira C. Toxidermies médicamenteuses: étude ambispective au Centre Hospitalier Universitaire Hassan II de FES [Thèse de Médecine] Université Mohammed V-SOUISSI 2014; N°29. [Drug-induced toxicity: an ambispective study at the Hassan II University Hospital of FES [Medical thesis] Mohammed V-SOUISSI University 2014; N°29].
- [12] Yang SC, Hu S, Zhang SZ, Huang JW. The epidemiology of Stevens Johnson Syndrome and Toxic Epidermal Necrolysis in China. J Immunol Res 2018; 11: 4320195.
- [13] Mario L, Pietro M, Antonio B, Corrado R. Toxic epidermal necrolysis (Lyell's disease). Burns J Int Soc Burn inj 2010; 36 (2): 152-63.
- [14] Tchetrya X, Ngwasiri CA, Munge T, Aminde LN. Severe eye complications from toxic epidermal necrolysis following initiation of Nevirapine based HAART regimen in a child with HIV infection: a case from Cameroon. BMC Pediatrics 2018; 18 (1): 108.